

Conflict of interest

None declared.

Funding

This study was supported by a Grant-in-Aid (Kiban C, 26460945) from the Ministry of Education, Culture, Sports, Science and Technology of Japan.

References

- [1] Hisamatsu T, Ueno F, Matsumoto T, et al. The 2nd edition of consensus statements for the diagnosis and management of intestinal Behcet's disease: indication of anti-TNFalpha monoclonal antibodies. *Journal of Gastroenterology* 2014;49:156–62.
- [2] Mizoshita T, Tanida S, Tsukamoto H, et al. Colon mucosa exhibits loss of ectopic MUC5AC expression in patients with ulcerative colitis treated with oral tacrolimus. *ISRN Gastroenterology* 2013;2013:304894.
- [3] Mizoshita T, Tanida S, Tsukamoto H, et al. Adalimumab treatment in biologically Naive Crohn's Disease: relationship with ectopic MUC5AC expression and endoscopic improvement. *Gastroenterology Research and Practice* 2014;2014:687257.
- [4] Lee HJ, Kim YN, Jang HW, et al. Correlations between endoscopic and clinical disease activity indices in intestinal Behcet's disease. *World Journal of Gastroenterology* 2012;18:5771–8.
- [5] Tanida S, Inoue N, Kobayashi K, et al. Adalimumab for the treatment of Japanese patients with intestinal Behcet's disease. *Clinical Gastroenterology and Hepatology* 2015;13:940–8.

Tsutomu Mizoshita*

Satoshi Tanida

Takashi Joh

*Department of Gastroenterology and Metabolism,
Nagoya City University Graduate School of Medical
Sciences, Nagoya, Japan*

*Corresponding author at: Department of Gastroenterology and Metabolism, Nagoya City University Graduate School of Medical Sciences, 1 Kawasumi, Mizuho-cho, Mizuho-ku, Nagoya 467-8601, Japan. Tel.: +81 52 853 8211; fax: +81 52 852 0952.
E-mail address: tmizoshi@med.nagoya-cu.ac.jp (T. Mizoshita)

<http://dx.doi.org/10.1016/j.dld.2015.07.007>

Extra-endoscopic mechanical lithotripsy of an impacted gallstone passing in the duodenum through a cholecystoduodenal fistula



Dear Editor,

An 83-year-old female was referred to our Department for abdominal pain and incoercible vomiting. Comorbidities included diabetes mellitus, chronic obstructive pulmonary disease, hypertension, asymptomatic coelithiasis. An upper gastrointestinal endoscopy showed a large gallstone impacted in the duodenal bulb associated with severe mucosal ulceration of the intestinal wall (Fig. 1A and B), expression of a bilio-enteric fistula. Surgical intervention was ruled out due to the patient's comorbidities.

After several endoscopic attempts, the impacted stone was removed from the duodenal bulb and placed in the stomach by the use of an endoscopic retrieval basket. The first lithotripsy attempt was performed by mechanical lithotripter. This endoscopic approach was unsuccessful due to rupture of the handle of the mechanical lithotripter. Thus, the wire basket of the broken

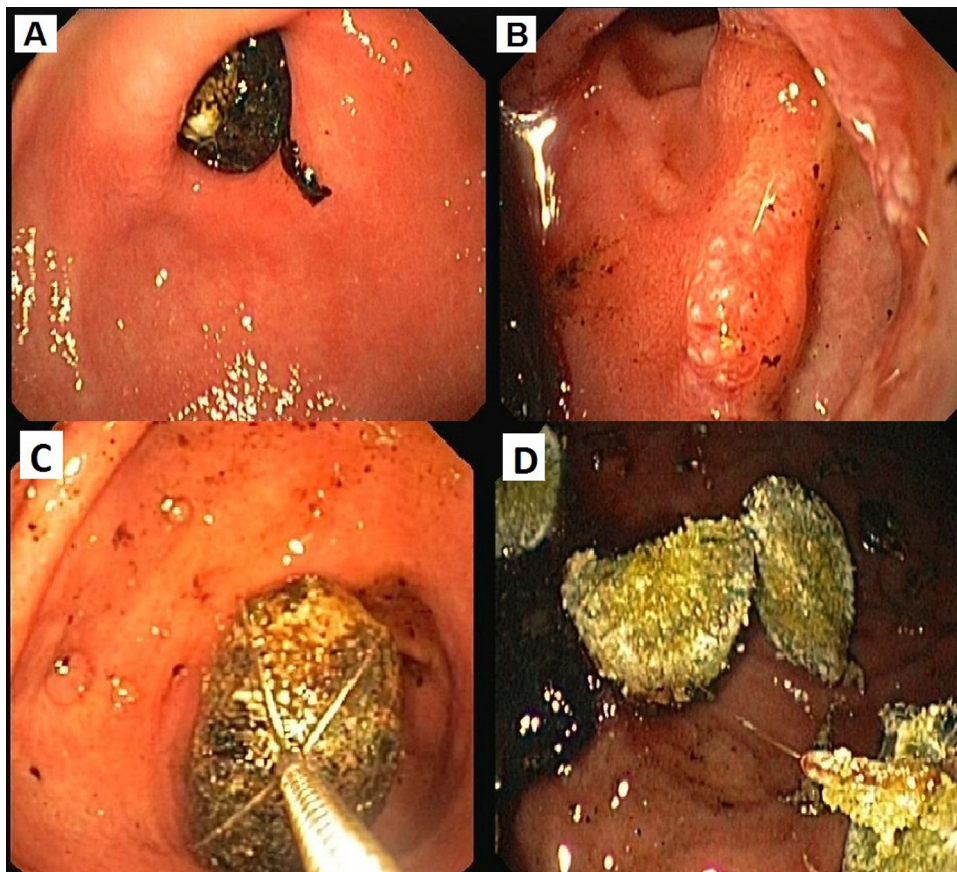


Fig. 1. (A) Endoscopic view of gallstone impacted in the duodenal bulb with (B) the presence of bilio-enteric fistula. (C) Gallstone captured in the basket of the mechanical extra-endoscopic lithotripter under direct endoscopic vision and (D) subsequent fragmentation.

lithotripter was removed from the stone by shaking the basket into the gastric lumen. A second attempt was subsequently performed with the extra-endoscopic Soehendra lithotripter (Soehendra lithotripter Cable, Cook Endoscopy, Winston-Salem, NC, USA) with parallel endoscopic view. The procedure allowed stone fragmentation with no immediate complications (Fig. 1C and D).

The patient had no further complications and was discharged after 7 days; at 2-month follow-up she was persistently asymptomatic.

Gastric outlet obstruction caused by an impacted gallstone penetrating the duodenal wall through a bilio-enteric fistula (defined also as Bouveret's syndrome) is a rare complication of cholelithiasis and it occurs most commonly in elderly women [1,2]. Clinical features are non-specific and are characterized by nausea, vomiting and abdominal pain [1,2]. Prompt diagnosis is important due to the high mortality rate, up to 30%, associated with surgery [2]. Endoscopy is the mainstay of diagnosis and abdominal computed tomography is useful when the diagnosis is not straightforward. In the majority of cases Bouveret's syndrome requires surgical intervention, and only few reports of successful endoscopic treatment have been published [2–4]. Nevertheless, endoscopic therapy should be considered as an effective non-surgical treatment option, particularly in patients with absolute or relative contraindications to surgery. To our knowledge, this is the first case describing successful endoscopic treatment of Bouveret's syndrome by intragastric extra-endoscopic mechanical lithotripsy.

Conflict of interest

None declared.

References

- [1] Antonini F, Belfiori V, Macarri G. Bouveret's syndrome: a rare complication of gallstone disease. *Liver International* 2013;33:1132.
- [2] Dai XZ, Li GQ, Zhang F, et al. Gallstone ileus: case report and literature review. *World Journal of Gastroenterology* 2013;19:5586–9.
- [3] Makker J, Muthusamy VR, Watson R, et al. Electrohydraulic lithotripsy and removal of a gallstone obstructing the duodenum: Bouveret syndrome. *Gastrointestinal Endoscopy* 2015;81:1021–2.
- [4] Tanwar S, Mawas A, Tutton M, et al. Successful endoscopic management of Bouveret's syndrome in a patient with cholecystoduodenocolic fistulae. *Case Reports in Gastroenterology* 2008;2:346–50.

Filippo Antonini*
Valerio Belfiori
Samuele De Minicis
Giampiero Macarri

*Department of Gastroenterology, A. Murri Hospital,
Polytechnic University of Marche, Fermo, Italy*

* Corresponding author. Tel.: +39 0734 6252249;
fax: +39 0734 6252252.

E-mail address: filippore@yahoo.it (F. Antonini)

<http://dx.doi.org/10.1016/j.dld.2015.08.009>